



Contents lists available at ScienceDirect

Archives of Gerontology and Geriatrics

journal homepage: www.elsevier.com/locate/archger

Tongue muscle mass is associated with total grey matter and hippocampal volumes in Dementia with Lewy Bodies

Miguel Germán Borda^{a,b,c,*}, Nicolás Castellanos-Perilla^{a,b}, Diego Alejandro Tovar-Rios^{a,c,d}, Daniel Ferreira^e, Gustavo Duque^{f,g}, Dag Aarsland^{a,h}

^a Centre for Age-Related Medicine (SESAM), Stavanger University Hospital, Stavanger, Norway

^b Semillero de Neurociencias y Envejecimiento, Ageing Institute, Medical School, Pontificia Universidad Javeriana, Bogotá, Colombia

^c Faculty of Health Sciences, University of Stavanger, Stavanger, Norway

^d Universidad del Valle, School of Statistics, Santiago de Cali, Colombia

^e Division of Clinical Geriatrics, Center for Alzheimer Research, Department of Neurobiology, Care Sciences and Society, Karolinska Institutet, Stockholm, Sweden

^f Department of Medicine-Western Health, Melbourne Medical School, University of Melbourne, Melbourne, Victoria, Australia

^g Australian Institute for Musculoskeletal Science (AIMSS), Geroscience and Osteosarcopenia Research Program, The University of Melbourne and Western Health, St. Albans, Melbourne, Victoria, Australia

^h Department of Old Age Psychiatry, Institute of Psychiatry, Psychology, and Neuroscience, King's College London, London, UK

ARTICLE INFO

Keywords:

Dementia
Intramuscular fat
Muscle
Dementia with Lewy Bodies
Alzheimer's disease
Sarcopenia

ABSTRACT

Background: Age-related neurodegeneration, sarcopenia, and ectopic fat accumulation are conditions with shared pathways that remain poorly understood. We have measured muscle volume and fat accumulation in masseter and tongue muscle, and aim to explore their association with the total grey matter volume using MRI in older adults recently diagnosed with Alzheimer's disease (AD) and Dementia with Lewy bodies (DLB).

Methods: In this cross-sectional study, people newly diagnosed with mild AD (n=33) and DLB (n=20) underwent structural head MRI. Muscle volume and intramuscular fat (iMAT) of the tongue and masseter were computed using Slice-O-Matic software for segmentation. Total grey volume and hippocampal volumetric segmentation were performed with the FreeSurfer image analysis suite version 6.0. Independent regression models were employed to analyse the associations.

Results: Tongue iMAT was higher and total grey volume lower in DLB compared to AD. In the DLB group, tongue muscle was positively associated with total grey matter volume Est 0.92 (SE 0.24 p-value 0.002), left- Est 0.01 (SE 0.0028 p-value 0,002), and right- Est 0.0088 (SE 0.0027 p-value: 0.005) hippocampal volume. There were no statistically significant results for AD.

Conclusion: Tongue muscle volume was positively associated with hippocampal and total grey volume in DLB. Longitudinal designs are required to explore the extent and significance of this association.

1. Introduction

With the increase in life expectancy, the older adult population has expanded, carrying an increase in dementia prevalence. Alzheimer's disease (AD) and Dementia with Lewy Bodies (DLB) are the most common causes of neurodegenerative dementia. (Cao et al., 2020) There are considerable variations in the clinical course, particularly in DLB; (Giil and Aarsland, 2020) thus, finding markers that detect people at risk of having a worse prognosis is crucial for planning and management. Sarcopenia, muscle volume and physical performance have recently been associated with cognitive decline, dementia onset and other

adverse outcomes. (Beeri et al., 2021; Peng et al., 2020) These conditions share common mechanisms with neurodegeneration, primarily through chronic inflammation, which has shown to be associated with malnutrition and body composition changes, including a decrease in muscular mass. (Ponti et al., 2020)

Muscle activation with physical activity (PA) has been linked to the maintenance of grey and white matter of the brain. (Cheng, 2016) Interventional studies with PA have shown increases in grey matter volumes, especially in the hippocampus and prefrontal cortex (Erickson et al., 2014). There is an association between the endocrinal function of the muscle stimulated during and after PA and the production of

* Corresponding author at: Centre for Age-Related Medicine (SESAM), Stavanger University Hospital, PB 8100, N-4068 Stavanger, Norway.
E-mail address: mmborda@gmail.com (M.G. Borda).

<https://doi.org/10.1016/j.archger.2022.104647>

Received 9 December 2021; Received in revised form 26 January 2022; Accepted 29 January 2022

Available online 1 February 2022

0167-4943/© 2022 The Author(s). Published by Elsevier B.V. This is an open access article under the CC BY license (<http://creativecommons.org/licenses/by/4.0/>).

inflammatory mediators such as myokines and other pleiotropic proteins like the brain-derived neurotrophic factor (BDNF). (Barcellos et al., 2020; Lee and Jun, 2019) In addition, studies exploring muscular function have shown a correlation between decreased muscular strength with grey matter atrophy and decreased cognitive performance. (Garcia-Cifuentes et al., 2017; Osawa et al., 2021; Raji et al., 2005)

Intramuscular fat (iMAT) are small fat deposits in the muscle, identified in case-control studies as potential contributor to mobility dysfunction in older adults and associated with the production of pro-inflammatory cytokines like interleukin (IL)-6. (Addison et al., 2014) iMAT may reflect muscular dysfunction, and it has been found to be a negative predictor of muscle and mobility performance in older individuals. (Addison et al., 2014) Still, the mechanism by which iMAT has a detrimental impact on muscle and mobility function is unclear. (Fontana et al., 2007; Raji et al., 2005) Standard methods to measure muscle volumes such as computed tomography or body MRI are expensive and not widely available, especially in dementia clinics. However, recent studies have addressed muscle mass measuring head and neck muscle volumes, which are convenient and inexpensive, avoiding the need for additional imaging, particularly in older persons with dementia. (Kilgour et al., 2013)

Muscles such as the tongue have roles such as deglutition and language production, properties that are closely related to sarcopenia and cognitive function. Previously, we showed that low tongue muscle volumes predict malnutrition in people with mild dementia. (Borda et al., 2021b) In the present study, we further investigated the association between muscle mass and neurodegeneration on standard head MRI. Specifically, we assessed the association of masseter and tongue muscle volumes as well as iMAT with total grey matter and hippocampal volumes in people diagnosed with mild AD and DLB.

2. Methods

"The Dementia Study of Western Norway" (DemVest) is a Norwegian longitudinal cohort study with a recruitment period between 2005 and 2013, and annual follow-up assessments are currently ongoing. Recruited participants were referrals to dementia clinics in the counties of Hordaland and Rogaland. The same National Insurance Scheme insured all inhabitants of the region. The complete methodology is detailed elsewhere. (Aarsland et al., 2008)

Exclusion criteria were moderate or severe dementia, delirium, past bipolar or psychotic condition, terminal illness, or newly diagnosed substantial somatic disease, which might significantly impact cognition, function, or participation.

For our current study, we included subjects clinically diagnosed with mild AD or DLB with an available MRI taken at baseline. From the initial sample $n=111$ (AD=85, DLB=26), we selected those who were assessed with the same scanner and had available good quality images for measuring brain and muscle variables, giving a final sample of 33 AD and 20 DLB participants.

2.1. Dementia diagnosis

Dementia diagnosis was made according to DSM-IV criteria, and patients were further classified using specific criteria for AD and DLB. Mild dementia was defined as a Mini-Mental Status Examination (MMSE) score of ≥ 20 or a Clinical Dementia Rating (CDR) global score of $= 1$. The diagnosis was performed from inclusion, however, it was susceptible to be modified according to clinical evolution, multidisciplinary consensus and autopsy. (Aarsland et al., 2008)

Patients were evaluated with structured assessments; essential information was obtained from medical records to gather complete and extensive data on each subject's medical background and comorbidities. Dopamine transporter SPECT scans were available for most patients with suspected DLB. Pathological diagnosis was made on 56 participants of the DemVest cohort, with an accuracy above 80% compared to the

clinical criteria. (Skogseth et al., 2017)

2.2. MRI acquisition

Participants were scanned under the same MRI device and protocol at Stavanger University Hospital, with a 1.5-T Philips Intera scanner. With the following acquisition protocol for 3D T1-weighted images: Repetition time (TR)/echo time (TE) 10.0/4.6 ms, flip angle 30°, number of excitations (NEX) 2, acquisition matrix 256×256, and voxel size: 1.0156×1.0156×1 mm". We conducted a visual quality check procedure, discarding images with movement artifacts and inadequate image quality. A standardized pre-processing method for harmonizing multiple collections of MRIs was applied, which consisted of movement correction and intensity normalization. Therefore, we excluded scans that had poor image quality. The same images were used to assess muscle volume and iMAT and brain volumes.

2.3. Calculations of Total Grey Matter and hippocampal Volumes

All the included patients had T1 weighted sequences. Following previously described methods, (Fischl and Dale, 2000) segmentation and parcellation of the cortical surface were carried out using FreeSurfer© 6.0, available for download online (<http://surfer.nmr.mgh.harvard.edu/>). The processing pipeline consisted of movements correction, non-brain tissue erasing, automated calculation of Talairach transformation, intensity normalization, subcortical white and grey matter segmentation, cortex boundary tessellation, fully automatic topology correction and surface deformation to determine CSF/grey matter and grey/white matter boundaries. The estimated total intracranial volume (TIV) measure was also selected from the FreeSurfer output and used in statistical analysis to account for variability in head size. (Voevodskaya et al., 2014)

2.4. Calculations of iMAT and muscle volume

Since this is a new method, we had to calibrate and determine the tissue thresholds for the scanner. Using the thresholds for tissues of interest, the volumes and volume ratios of muscle, iMAT, and subcutaneous fat (SAT) were manually tagged and quantified from the regions of interest using Slice-O-Matic (Montreal, CA) software (Figure 1A) as previously described (Bani Hassan et al., 2018) Figure 1.

2.5. Other variables

As potential confounders were considered demographic factors such as gender and age, BMI calculated using body weight and height with the formula $BMI = \text{weight (kg)}/\text{height (m)}^2$, comorbidities using the Cumulative Illness Rating Scale (CIRS) based on patient and informant reports, motor symptoms using the Unified Parkinson's Disease Rating Scale part III (UPDRS III), and global cognitive performance using the Norwegian version of the Mini-Mental State Examination (MMSE).

2.6. Statistical Analysis

We calculated the percentages for categorical variables and mean and standard deviation for continuous variables. We used the exact Fisher's test to evaluate independence between groups (AD/DLB) and sex. To compare the mean of continuous variables between groups, we performed the t-test. Independent regression models were fitted for the left and right hippocampus and the total grey volume after dividing each measure by the TIV to adjust for head size across subjects. The relationship between tongue muscle volumes and iMAT with the other variables of interest was carried out in independent regression models due to the sample's small number of available observations. Age, Sex, MMSE, BMI, UPDRS III, and CIRS, were considered for adjustment by performing a stepwise variable selection, and we established statistical

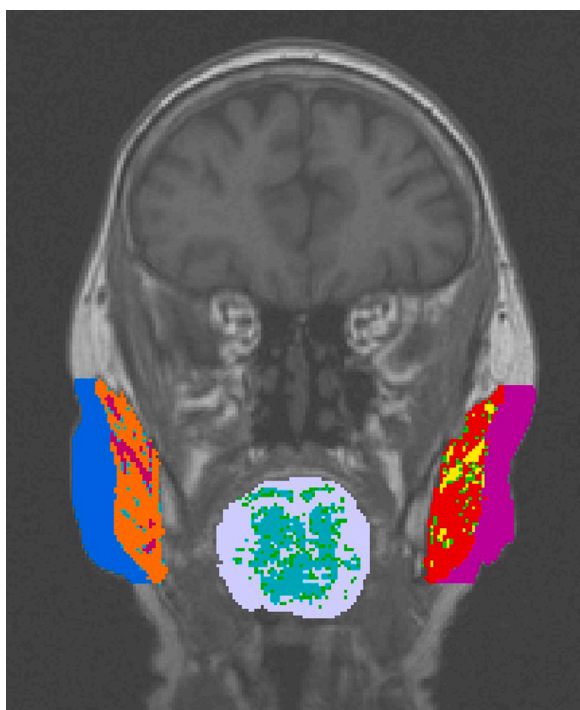


Fig. 1. Segmented cerebral MRI slice in which the muscles and intramuscular fat (iMAT) of the tongue and right and left subcutaneous fat, masseter muscles, and masseter iMAT have been tagged with different colours for quantification.

significance at 0.05. All procedures and graphs were made using R software v4.0.5, R Foundation for Statistical Computing, Vienna, Austria.

3. Results

There were baseline differences between the groups in tongue iMAT (AD 0.51 ± 0.91 , DLB 1.29 ± 1.42 p-value=0.018) and total grey matter

Table 1
Study characteristics.

	AD n (%) or mean \pm sd	DLB n (%) or mean \pm sd	Total n (%) or mean \pm sd	P- value
Total	33 (62.26)	20 (37.74)	53 (100.00)	
Gender				<0.01
Male	9 (27.27)	16 (80.00)	25 (47.17)	
Female	24 (72.73)	4 (20.00)	28 (52.83)	
Age	76.51 \pm 7.04	75.64 \pm 6.05	76.18 \pm 6.64	0.649
MMSE	23.39 \pm 3.14	23.25 \pm 3.14	23.34 \pm 2.81	0.859
UPDRS III	1.03 \pm 1.71	12.00 \pm 11.88	4.85 \pm 8.77	<0.01
Tongue Muscle	6.58 \pm 2.19	5.58 \pm 2.46	6.20 \pm 2.32	0.127
Tongue iMAT	0.51 \pm 0.91	1.29 \pm 1.42	0.81 \pm 1.18	0.018
Left Masseter Muscle	2.44 \pm 0.83	2.71 \pm 0.79	2.54 \pm 0.82	0.262
Left Masseter iMAT	0.50 \pm 0.54	0.68 \pm 0.63	0.57 \pm 0.58	0.274
Right Masseter Muscle	2.71 \pm 0.91	3.12 \pm 1.04	2.86 \pm 0.97	0.140
Right Masseter iMAT	0.43 \pm 0.68	0.50 \pm 0.55	0.46 \pm 0.63	0.684
% Left hippocampus	0.22 \pm 0.04	0.21 \pm 0.03	0.22 \pm 0.03	0.609
% Right hippocampus	0.22 \pm 0.04	0.21 \pm 0.03	0.22 \pm 0.04	0.261
% Total grey volume	37.37 \pm 3.49	34.91 \pm 3.45	36.45 \pm 3.65	0.016
Estimated TIV x1000000	1.42 \pm 0.16	1.60 \pm 0.18	1.49 \pm 1.19	<0.01

AD: Alzheimer Disease, DLB: Dementia with Lewy Bodies, MMSE: Minimal state assessment, UPDRS III: Unified Parkinson's Disease Rating Scale part III (iMAT: Intramuscular fat, TIV: total Intracranial Volume, sd: standard deviation

volume (AD 37.37 ± 3.49 , DLB 34.91 ± 3.45 p-value=0.016). Detailed descriptive analyses are shown in Table 1.

After adjustments by age, sex and cognition, in the DLB group, smaller tongue muscle was associated with less total grey volume Est 0.92 (SE 0.24, p-value 0.002) and lower left Est 0.01 (SE 0.0028 p-value 0.002) and right Est 0.0088 (SE 0.0027 p-value: 0.005) hippocampal volumes. In AD there were not significant results. (Table 2 and Figure 2). See appendix 1 for unadjusted analysis and appendix 2 for adjusted analysis of tongue iMAT and masseter muscle.

4. Discussion

We found a positive association between tongue muscle volume with the left and right hippocampal volumes and the total grey matter volumes in the DLB group, even after controlling for confounding factors. There were no significant brain-muscle volume associations in AD. Sarcopenia and muscular condition are important prognostic factors in many disorders, including dementia. (Beeri et al., 2021) Therefore, in people with this condition, in which head MRI is a common practice, muscle volumes could be more systematically and opportunistically measured using tongue muscle.

In previous studies, brain mass has been related to total muscular lean mass.(Burns et al., 2010) In people living with AD, reduced muscular lean mass measured with DEXA has been related to brain atrophy and cognitive performance. (Lee et al., 2021) The ratio of thigh muscle to visceral fat measured with CT and MRI has shown correlations with entorhinal cortex, temporal pole, and inferior temporal gyrus volumes. (Lee et al., 2021) In addition, the neck muscle cross-sectional area

Table 2

Adjusted model. Total grey volume and R&L hippocampus/ intracranial volume. See appendix 2 for unadjusted models. And adjusted tongue iMAT and masseter models.

	Alzheimer Disease Est	Std Err	P- value	Dementia with Lewy Bodies Est	Std Err	P- value
<u>Total grey volume</u>						
Intercept	3.9	9.3	<0.001	5.3	1.3	0.001
	E+01	E+00		E+01	E+01	
Tongue Muscle	1.5.E-02	3.1.E-01	0.961	9.2.E-01	2.4.E-01	0.002
Age BL	-1.1.E-01	9.3.E-02	0.230	-2.8.E-01	1.2.E-01	0.030
Male vs Female	2.0	1.4	0.163	5.2	1.5	0.004
MMSE	2.5.E-01	2.4.E-01	0.306	-1.2.E-01	2.4.E-01	0.638
<u>Left hippocampus</u>						
Intercept	8.5.E-02	9.4.E-02	0.372	6.0.E-01	1.5.E-01	0.001
	02	02		01	01	
Tongue Muscle	2.4.E-03	3.1.E-03	0.456	1.0.E-02	2.8.E-03	0.002
Age BL	2.3.E-04	9.4.E-04	0.808	-4.4.E-03	1.4.E-03	0.006
Male vs Female	1.1.E-02	1.4.E-02	0.427	3.0.E-02	1.8.E-02	0.111
MMSE	3.9.E-03	2.4.E-03	0.115	-5.0.E-03	2.8.E-03	0.096
	03	03		03	03	
<u>Right hippocampus</u>						
Intercept	9.2.E-02	1.1.E-01	0.403	3.5.E-01	1.4.E-01	0.026
	02	01		01	01	
Tongue Muscle	2.3.E-03	3.6.E-03	0.540	8.8.E-03	2.7.E-03	0.005
Age BL	7.4.E-05	1.1.E-03	0.947	-2.2.E-03	1.3.E-03	0.112
Male vs Female	1.8.E-02	1.6.E-02	0.258	1.9.E-02	1.7.E-02	0.274
MMSE	4.1.E-03	2.8.E-03	0.153	-1.2.E-03	2.7.E-03	0.673
	03	03		03	03	

Est: Estimation, BL: Baseline, Std Err: Standard Error, MMSE: Minimal state assessment

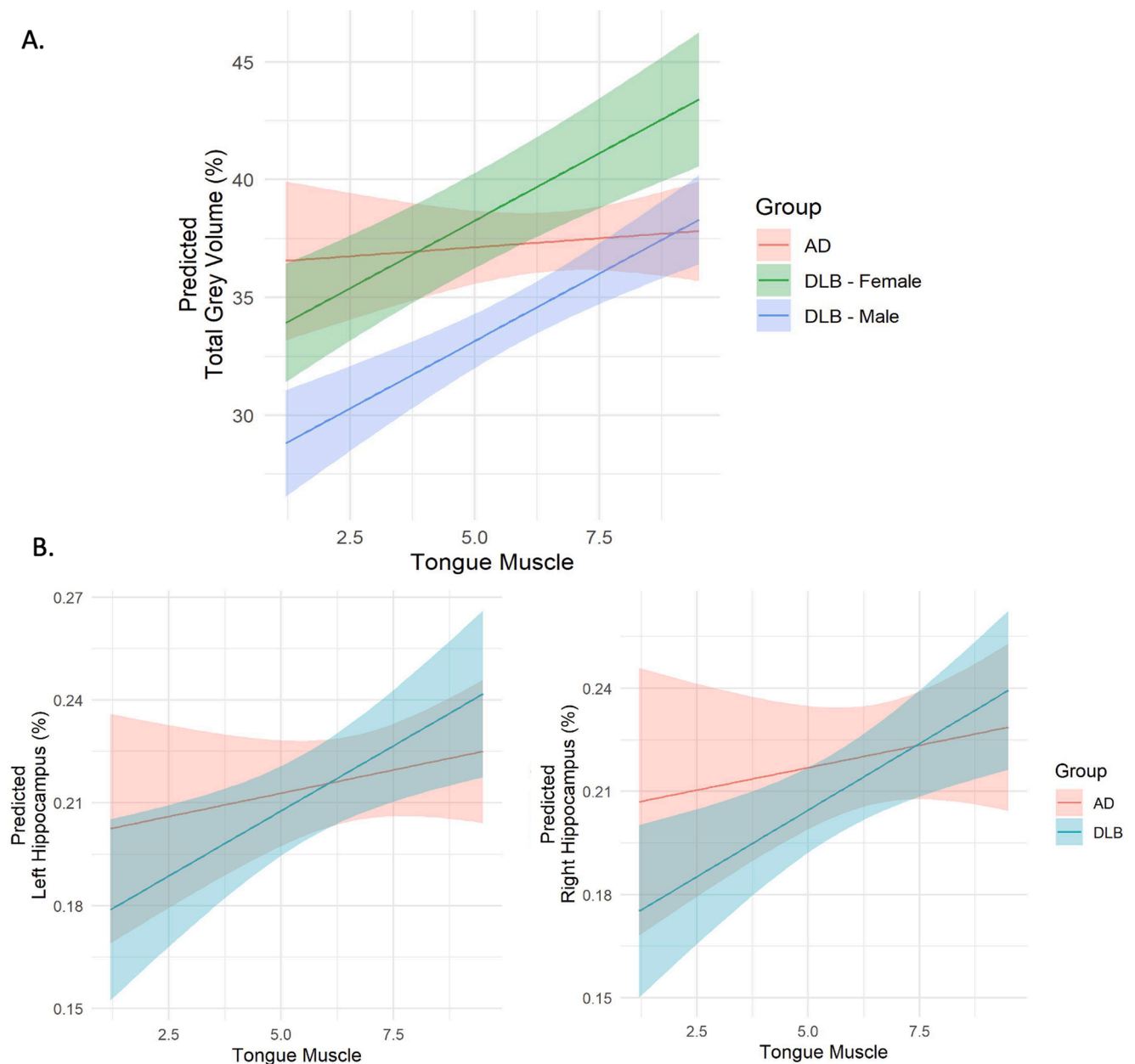


Fig. 2. AD: Alzheimer Disease, DLB: Dementia with Lewy Bodies. A. Relationship between tongue muscle and total grey volume. B. Relationship between tongue muscle with Left and right hippocamp.

(CSA) measured with MRI has been related to less brain atrophy. (Kilgour et al., 2013)

Previous research by Kilgour et al. reported a positive association between brain volumes with neck muscle mass and total grey volume in healthy older men. (Kilgour et al., 2013) Our study is one of the first to assess masticatory muscle volumes and iMAT in relation to brain volumes and the first in people living with DLB.

Fat infiltration occurs together with muscle loss, further impairing muscle mass and function. (Marcus et al., 2012) Because of a large amount of muscle in the human body, slight infiltrations of ectopic fat into muscles can result in the local and systemic production of lipotoxic adipokines and fatty acids. (Marcus et al., 2012) iMAT has been shown to have negative implications on mobility and function in older adults. Muscle fat infiltration is an important factor contributing to motor deficits and systemic inflammation in this population. (Marcus et al., 2012) However, we did not find significant associations between iMAT and any of the studied variables. Nevertheless, this could be different in

more advanced dementia stages.

Just like any other muscle, tongue muscle volumes decrease with aging and are affected by sarcopenia. (King and Thomas, 2017) In addition, skeletal muscle express several myokines, such as BDNF, recognized as playing a pivotal role in regulating the survival, growth and maintenance of neurons. (Mattson et al., 2004; Pedersen, 2019) In addition, muscle function depends on an adequate nutritional status, and tongue muscular groups are important for deglutition which has been associated with a higher probability of malnutrition. Our group explored this association where tongue muscle and its iMAT were associated with an increased risk of developing malnutrition in the same cohort. (Borda et al., 2021b)

The associations were significant only for DLB cases. People living with DLB tend to be more frail from diagnosis, with more comorbidity, neuropsychiatric symptoms, malnutrition, and therefore muscular impairment could be more pronounced. Interestingly, we found reduced muscle and more iMAT in DLB than AD; even at the same age and level of

cognitive impairment. (Borda et al., 2020; Borda et al., 2021a) This, in addition to greater systemic inflammation in DLB as a common mechanism for neurodegeneration and muscle damage. (King and Thomas, 2017) Furthermore, dysphagia could be a consequence of this masticatory muscle damage, which is already frequent in dementia and more common during mild stages in people diagnosed with DLB. (Alagiakrishnan et al., 2013) Tongue muscle volume could therefore represent an early marker of brain atrophy in DLB patients. Longitudinal studies testing this hypothesis are required.

There are some limitations to this study. Selection bias might have occurred if a larger number of patients with more complex health conditions had been chosen since the Demvest study included primary care referrals. On the other hand, general practitioners were encouraged to refer anyone suspected of having dementia. The DEMVEST study was not designed for the purpose of this paper, which generates possible limitations when analysing the data and controlling interactions. In addition, the lack of comparison with a healthy control group did not allow to evaluate whether the studied participants were different from healthy older adults. Conditions that were not investigated, such as missing teeth, bruxism, rigidity in DLB, or dental prosthesis, might affect muscle volumes. Some limitations to the automated segmentation approach include thresholds and the operator's experience. Slice-O-Matic measures, on the other hand, have been verified against gold standards in the past, exhibiting excellent inter- and intra-rater reliability, as well as good reliability and validity. (Demontiero et al., 2011) The sample size was small due to imaging availability and quality selection, and longitudinal analyses were not performed because images were only available at baseline.

5. Conclusion

Tongue muscle volume at diagnosis was associated with total grey and hippocampal volume in DLB, indicating that measuring the tongue muscle can offer a simple, non-invasive and cost-effective measurement of muscle volume since most patients with suspected or confirmed dementia will have MRI scans. This method can thus be applied for research and clinical purposes. Further longitudinal investigations are required to explore the association between tongue muscle and prognosis.

6. Authors contribution

Miguel Germán Borda: Conception of work, Formal analysis, Methodology, Preparation of the initial draft, Visualization, Writing-Reviewing and Editing.

Nicolás Castellanos-Perilla: Formal analysis, Methodology, Preparation of the initial draft, Visualization, Writing- Reviewing and Editing.

Diego Alejandro Tovar-Rios: Formal analysis, Writing- Reviewing and Editing.

Daniel Ferreira: Methodology, Visualization, Writing- Reviewing and Editing, supervision.

Gustavo Duque: Methodology, Visualization, Writing- Reviewing and Editing, supervision.

Dag Aarsland: Methodology, Visualization, Writing- Reviewing and Editing, supervision.

Declaration of Competing Interest

The authors have no conflicts of interest to declare. The funders had no role in the design of the study, in the collection, analyses, or interpretation of data, in the writing of the manuscript, or in the decision to publish the results. The views expressed are those of the author(s) and not necessarily those of the NHS, the NIHR, or the Department of Health and Social Care.

Acknowledgments

We want to thank the participants, researchers, and technical staff that made the DemVest study possible, as well as staff and facilities provided by (SESAM) Centre for age-related medicine at Stavanger, Norway. In addition to Ebrahim Bani Hassan, Jang Ho Weon, Mahdi Imani and Ketil Oppedal for their contribution to imaging processing procedures.

Funding information

This work was supported by the Norwegian government through hospital owner Helse Vest (Western Norway Regional Health Authority) number 911973. It is also funded by the National Institute for Health Research (NIHR) Biomedical Research Centre at South London and Maudsley NHS Foundation Trust, and King's College London.

Supplementary materials

Supplementary material associated with this article can be found, in the online version, at [doi:10.1016/j.archger.2022.104647](https://doi.org/10.1016/j.archger.2022.104647).

References

- Aarsland, D., Rongve A Fau - Nore, S.P., Nore Sp Fau - Skogseth, R., Skogseth R Fau - Skulstad, S., Skulstad S Fau - Ehrt, U., Ehrt U Fau - Hoprekstad, D. et al. (2008). Frequency and case identification of dementia with Lewy bodies using the revised consensus criteria.
- Addison, O., Drummond, M. J., LaStayo, P. C., Dibble, L. E., Wende, A. R., McClain, D. A., et al. (2014). Intramuscular fat and inflammation differ in older adults: The impact of frailty and inactivity. *Journal of Nutrition, Health and Aging*, *18*, 532–538.
- Alagiakrishnan, K., Bhanji, R. A., & Kurian, M. (2013). Evaluation and management of oropharyngeal dysphagia in different types of dementia: A systematic review. *Archives of Gerontology and Geriatrics*, *56*, 1–9.
- Bani Hassan, E., Demontiero, O., Vogrin, S., Ng, A., & Duque, G. (2018). Marrow Adipose Tissue in Older Men: Association with Visceral and Subcutaneous Fat, Bone Volume, Metabolism, and Inflammation. *Calcified Tissue International*, *103*, 164–174.
- Barcellos, N., Cechinel, L. R., de Meireles, L. C. F., Lovatel, G. A., Bruch, G. E., Carregal, V. M., et al. (2020). Effects of exercise modalities on BDNF and IL-1 β content in circulating total extracellular vesicles and particles obtained from aged rats. *Experimental Gerontology*, *142*, Article 111124.
- Beeri, M. S., Leurgans, S. E., Delbono, O., Bennett, D. A., & Buchman, A. S. (2021). Sarcopenia is associated with incident Alzheimer's dementia, mild cognitive impairment, and cognitive decline. *Journal of the American Geriatrics Society*, *69*, 1826–1835.
- Borda, M. G., Aarsland, D., Tovar-Rios, D. A., Giil, L. M., Ballard, C., Gonzalez, M. C., et al. (2020). Neuropsychiatric Symptoms and Functional Decline in Alzheimer's Disease and Lewy Body Dementia. *Journal of the American Geriatrics Society*, *68*, 2257–2263.
- Borda, M. G., Ayala Copete, A. M., Tovar-Rios, D. A., Jaramillo-Jimenez, A., Giil, L. M., Soenensyn, H., et al. (2021a). Association of Malnutrition with Functional and Cognitive Trajectories in People Living with Dementia: A Five-Year Follow-Up Study. *Journal of Alzheimer's Disease*, *79*, 1713–1722.
- Borda, M. G., Bani Hassan, E., Weon, J., Wakabayashi, H., Tovar-Rios, D. A., Oppedal, K., et al. (2021b). Muscle volume and intramuscular fat of the tongue evaluated with MRI predict malnutrition in people living with dementia: A five-year follow-up study. *Journals of Gerontology. Series A, Biological Sciences and Medical Sciences*.
- Burns, J. M., Johnson, D. K., Watts, A., Swerdlow, R. H., & Brooks, W. M. (2010). Reduced lean mass in early Alzheimer disease and its association with brain atrophy. *Archives of Neurology*, *67*, 428–433.
- Cao, Q., Tan, C. C., Xu, W., Hu, H., Cao, X. P., Dong, Q., et al. (2020). The Prevalence of Dementia: A Systematic Review and Meta-Analysis. *Journal of Alzheimer's Disease*, *73*, 1157–1166.
- Cheng, S. T. (2016). Cognitive Reserve and the Prevention of Dementia: The Role of Physical and Cognitive Activities. *Current Psychiatry Reports*, *18*, 85.
- Demontiero, O., Li, W., Thembani, E., & Duque, G. (2011). Validation of noninvasive quantification of bone marrow fat volume with microCT in aging rats. *Experimental Gerontology*, *46*, 435–440.
- Erickson, K. I., Leckie, R. L., & Weinstein, A. M. (2014). Physical activity, fitness, and gray matter volume. *Neurobiology of Aging*, *35*(Suppl 2), S20–S28.
- Fischl, B., & Dale, A. M. (2000). Measuring the thickness of the human cerebral cortex from magnetic resonance images. *Proceedings of the National Academy of Sciences*, *97*, 11050–11055.
- Fontana, L., Eagon, J. C., Trujillo, M. E., Scherer, P. E., & Klein, S. (2007). Visceral fat adipokine secretion is associated with systemic inflammation in obese humans. *Diabetes*, *56*, 1010–1013.
- García-Cifuentes, E., David-Pardo, D. G., Borda, M. G., Perez-Zepeda, M. U., & Cano-Gutiérrez, C. A. (2017). TWO-WAY Bridge between Muscular Dysfunction and

- Cognitive Impairment: Secondary Analyses of SABE - Bogota Study. *Journal of Frailty Aging*, 6, 141–143.
- Giil, L. M., & Aarsland, D. (2020). Greater Variability in Cognitive Decline in Lewy Body Dementia Compared to Alzheimer's Disease. *Journal of Alzheimer's Disease*, 73, 1321–1330.
- Kilgour, A. H. M., Ferguson, K. J., Gray, C. D., Deary, I. J., Wardlaw, J. M., MacLulich, A. M. J., et al. (2013). Neck muscle cross-sectional area, brain volume and cognition in healthy older men; a cohort study. *BMC Geriatrics*, 13, 20.
- King, E., & Thomas, A. (2017). Systemic Inflammation in Lewy Body Diseases: A Systematic Review. *Alzheimer Disease and Associated Disorders*, 31, 346–356.
- Lee, H., Seo, H. S., Kim, R. E., Y., Lee, S. K., Lee, Y. H., & Shin, C. (2021). Obesity and muscle may have synergic effect more than independent effects on brain volume in community-based elderly. *European Radiology*, 31, 2956–2966.
- Lee, J. H., & Jun, H.-S. (2019). Role of Myokines in Regulating Skeletal Muscle Mass and Function. *Frontiers in Physiology*, 10.
- Marcus, R. L., Addison, O., Dibble, L. E., Foreman, K. B., Morrell, G., & Lastayo, P. (2012). Intramuscular adipose tissue, sarcopenia, and mobility function in older individuals. *Journal for Aging Research* 2012, Article 629637.
- Mattson, M. P., Maudsley, S., & Martin, B. (2004). BDNF and 5-HT: A dynamic duo in age-related neuronal plasticity and neurodegenerative disorders. *Trends in Neuroscience (Tins)*, 27, 589–594.
- Osawa, Y., Tian, Q., An, Y., Studenski, S. A., Resnick, S. M., & Ferrucci, L. (2021). Longitudinal Associations Between Brain Volume and Knee Extension Peak Torque. *Journals of Gerontology. Series A, Biological Sciences and Medical Sciences*, 76, 286–290.
- Pedersen, B. K. (2019). Physical activity and muscle-brain crosstalk. *Nature reviews Endocrinology*, 15, 383–392.
- Peng, T. C., Chen, W. L., Wu, L. W., Chang, Y. W., & Kao, T. W. (2020). Sarcopenia and cognitive impairment: A systematic review and meta-analysis. *Clinical Nutrition*, 39, 2695–2701.
- Ponti, F., Santoro, A., Mercatelli, D., Gasperini, C., Conte, M., Martucci, M., et al. (2020). Aging and Imaging Assessment of Body Composition: From Fat to Facts. *Frontiers in Endocrinology*, 10.
- Raji, M. A., Kuo, Y. F., Snih, S. A., Markides, K. S., Peek, M. K., & Ottenbacher, K. J. (2005). Cognitive status, muscle strength, and subsequent disability in older Mexican Americans. *Journal of the American Geriatrics Society*, 53, 1462–1468.
- Skogseth, R., Hortobágyi, T., Soennesyn, H., Chwiszczuk, L., Ffytche, D., Rongve, A., et al. (2017). Accuracy of Clinical Diagnosis of Dementia with Lewy Bodies versus Neuropathology. *Journal of Alzheimer's Disease*, 59, 1139–1152.
- Voevodskaya, O., Simmons, A., Nordenskjöld, R., Kullberg, J., Ahlström, H., Lind, L., & A.s.D.N.I. (2014). The effects of intracranial volume adjustment approaches on multiple regional MRI volumes in healthy aging and Alzheimer's disease. *Frontiers in Aging Neuroscience*, 6.